

## Rheumatoid Vasculitis and Blepharitis Caused By Rheumatoid Arthritis In 6 Years Old Boy: A Case Report



Sitti Aizah Lawang<sup>1\*</sup>, Hasriani Muhammad Hakka<sup>2</sup>, Mulawardi Muhammad Nurdin<sup>3</sup>,  
Destya Maulani<sup>4</sup>

### ABSTRACT

**Introduction:** Rheumatoid Vasculitis (RV) is a rare complication affecting approximately 1% of patients with severe rheumatoid arthritis. This condition is an extra-articular manifestation of rheumatoid arthritis that affects the small and medium arteries in the body. Vasculitis is an inflammatory necrotizing vascular wall disease that can occur in autoimmune disease. This inflammation leads to damage in blood vessels due to stenosis or occlusion and thrombosis, resulting in pain, necrosis, and aneurysm. Inflammation can be primary or secondary. Skin, fingers, peripheral nerves, eyes and the heart are the most commonly affected areas.

**Case description:** We report a case of a 6-year-old boy who presented RV and blepharitis. The patient subsequently experienced nail fold infarcts and gangrene of his left finger. He was found to fulfill Jones Criteria, and treatment with aspirin and corticosteroids significantly improved his symptoms. This rare case describes the early onset of rheumatoid vasculitis in a patient with rheumatoid arthritis. Rheumatoid vasculitis is a systemic disease that develops from rheumatoid arthritis with rheumatoid autoantibodies and extra-articular manifestations characterized by tissue damage or ischemia involving the skin and peripheral nerves. The incidence of rheumatoid vasculitis in children is less than 1%, with 12 to 53 cases per 100,000 children under 17 years old.

**Conclusion:** Rheumatoid vasculitis is a rare complication of rheumatoid. This condition occurs in patients who have rheumatoid arthritis for a long period. The patient will prevent further complications with early diagnostic and proper treatment.

**Keywords:** Rheumatoid Vasculitis, Children, Rare Case.

**Cite This Article:** Lawang, S.A., Hakka, H.M., Nurdin, M.M., Maulani, D. 2023. Rheumatoid Vasculitis and Blepharitis Caused By Rheumatoid Arthritis In 6 Years Old Boy: A Case Report. *Bali Medical Journal* 12(3): 2963-2967. DOI: 10.15562/bmj.v12i3.4789

<sup>1</sup>Department of Pediatric, Faculty of Medicine, Universitas Hasanuddin, Indonesia;

<sup>2</sup>Department of Pediatric, Faculty of Medicine, Universitas Hasanuddin, Wahidin Sudirohusodo Hospital, Indonesia;

<sup>3</sup>Department of Vascular Surgery, Wahidin Sudirohusodo Hospital, Indonesia;

<sup>4</sup>Department of Pediatric, Faculty of Medicine, Universitas Hasanuddin, Haji Hospital, Indonesia.

\*Corresponding author:

Sitti Aizah Lawang;  
Department of Pediatric, Faculty of Medicine, Universitas Hasanuddin, Indonesia. Makassar City, Indonesia;  
[staizahlawang07@gmail.com](mailto:staizahlawang07@gmail.com)

Received: 2023-06-14

Accepted: 2023-09-01

Published: 2023-10-07

### INTRODUCTION

Rheumatoid vasculitis is a systemic disease that develops from rheumatoid arthritis with rheumatoid autoantibodies and extra-articular manifestations characterized by tissue damage or ischemia involving the skin and peripheral nerves.<sup>1</sup> The incidence of rheumatoid vasculitis in children is less than 1%, with 12 to 53 cases per 100,000 children under 17. Gross *et al* observed coronary vasculitis in 33% patients with rheumatic heart disease.<sup>1,2</sup> Rheumatic heart disease (RHD) is caused by a delayed immunological response following group A streptococcus  $\beta$  haemolytic (*group A  $\beta$ -hemolytic Streptococcus/GABHS*) infection, which occurs acutely or recurrently with one or more major symptoms including acute polyarthritis migrans, carditis, chorea, subcutaneous nodules, and erythema marginatum.<sup>3,4</sup>

Rheumatic heart disease remains a major public health concern in developing countries. In 2004, the World Health Organization estimated that approximately 15.6 million people worldwide suffered from rheumatic heart disease. Within a year, 300,000 of the 1.5 million people with acute rheumatic fever will develop rheumatic heart disease. According to a case study of rheumatic heart disease in 2015, there were 33.4 million case worldwide with 10.5 million cases of rheumatic heart disease-associated morbidities and 319,400 deaths. Oceania, central Sub-Saharan Africa, and South Asia have the highest rate of rheumatic heart disease.<sup>3</sup> Age group 5- 15 years has the highest incidence with peak incidence at 8 years of age, while rarely found in children under 4 years old.<sup>5,6</sup> This paper reported one case of a 6-year-old boy

with rheumatoid vasculitis and unilateral blepharitis due to rheumatic heart disease.

### CASE REPORT

A 6 years 6 months old boy came to the hospital with dyspnea since 4 months before admission, worsening in the last 1 week and worsens with activity, there was no coughing nor cyanosis. History of fever for one week and frequent fever since about 5 months prior to admission. There was reddish swelling of the right eyelid with tenderness and discharge which was noted since 4 days before hospitalization. There were also rash on the arms and legs since the last 2 weeks, but with no tenderness nor itching. Dark wound at the tips of digiti 1 and 2 as well as knee joint stiffness on both legs, experienced since 4 months ago and No history of family with

similar condition.

There was history of rash on the skin over the last two years. History of fatigue since 4 months before admission, and history of pain in the pelvis 5 months ago. Physical examination: nutritional status BW: 13,5 kg (severely wasted). Right palpebral is edematous and erythematous, no pain with some discharge. Hyperemic conjunctiva and unremarkable eye movement. Lung: rales on both lungs. Heart: Heart Sound I-II regular systolic murmur grade 3/6. Increased JVP 5+4 cmH<sub>2</sub>O Erythematous maculopapular rash on all extremities, gangrenous lesion on distal digiti I, II of left hand.

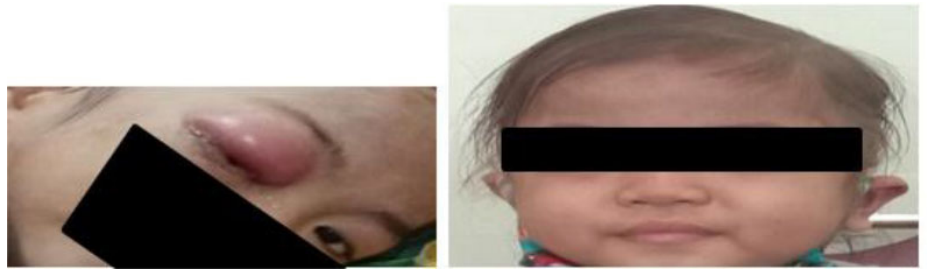Laboratory examination showed Hb 7,9 g/dl, WBC 22.500/mm<sup>3</sup>, platelet 967.000, CRP 78,5 mg/l, ESR I/II 86/125 mm/hour, ASTO 3878 IU/dl, Ferritin >1200. Peripheral blood smear: normocytic normochromic anemia, suspected infection, reactive thrombocytosis. Comb's test: positive. PT/APTT: 11,8/26,4. ANA profile: <10. Blood culture: no growth. Chest x ray: bilateral pneumonia and cardiomegaly. Echocardiography: decrease systolic LV Ef 35 % with LA/LV dilatation, mild-moderate mitral regurgitation as in rheumatic heart disease. MSCT angiography of left upper extremity: Left deep palmaris arch: Lumen if the radial finger artery was constricted, but there were no aneurysms or other congenital anomalies. Impression: suspected left index finger radialis artery stenosis. Consult to ophthalmology: right superior blepharitis, no vision loss. Tissue biopsy from finger: Vasculitis with angioma can be considered.

**Final Diagnosis**

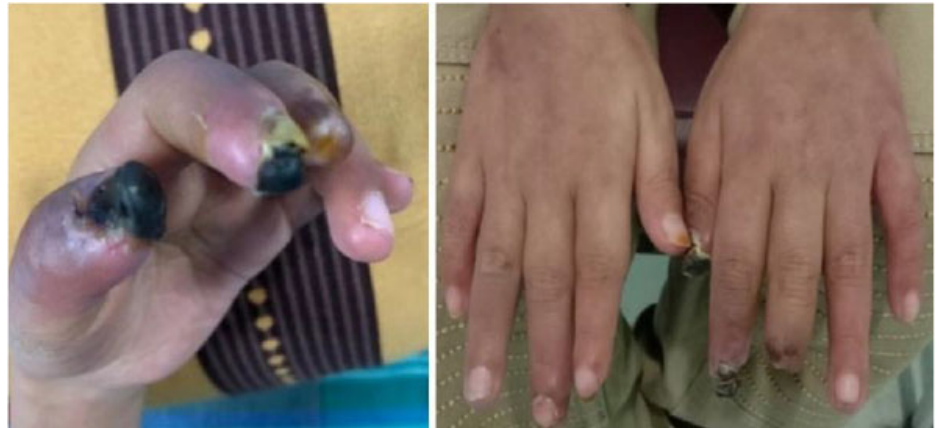Left and right heart failure due to acquired heart disease caused by rheumatic heart disease, rheumatoid vasculitis, upper right blepharitis, malnourished, chronic disease anemia.

**Hospital Course**

The patient was admitted with working diagnosis of RV based on Jones Criteria of major criteria (carditis) and minor criteria (arthralgia, leukocytosis, increased CRP, increased ESR and increased Anti-streptolysin O titer). The patient suffered from RV with heart failure. Prognosis in



**Figure 1.** Blepharitis. (A-left) Day-1 before treatment. (B-right) Day-27 after treatment.



**Figure 2.** (A-left) RV at admission. (B-right) RV at day-30 after treatment.

this patient dubia because the rheumatoid arthritis already with complication. The treatment were given diuretic, inotropic and ACE inhibitor were given for heart failure. The treatment for RV was prednisone/methylprednisolone 2 mg/kg/day. Erythromycin was given for streptococcus eradication, because benzathine penicillin was not available. Aspirin 350 mg/6hour/oral was given for 3 weeks and prednisone was tapered off. Anemia chronic disease resulting in hemoglobin level of 7,9 g/dl, therefore PRC transfusion was administered.

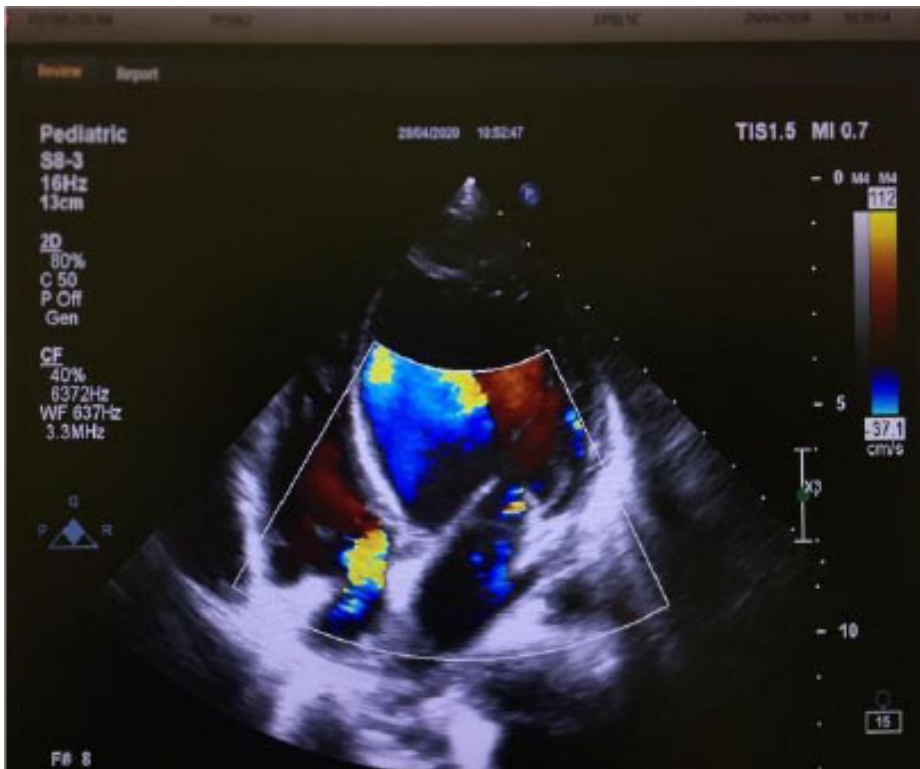
Vascular surgery department gave intravenous heparin 75 unit/kg and suggest to perform CT angiography. CT angiography revealed a possible stenosis of the left index finger radialis artery. Heparin was given for two weeks but no improvement on necrotic ulcerative lesion digiti I,II *manus sinistra*, amputation was proposed but family refused. Heparin was discontinued following vasculitis result on biopsy. Our patient also received xytrol zalf/8hour/OD, Levofloxacin ED 1 gtt/8hour/OD for blepharitis from the ophthalmology department for 2 weeks, but no improvement was observed. The necrotic ulcerative lesion

and blepharitis were improved following aspirin administration. After 30 days of hospitalization necrotic tissues in the hand were improved, while no longer necrotic tissues were observed on the feet, no blepharitis nor malnourished, body weight increased to 16,5 kg. The patient was discharged. The patient was control post discharge to the outpatient clinic. The patient tolerant with the drug and treatment and no adverse event.

Treatments were continued, tapering off methylprednisolone 1 mg/kgbw/day, dobutamine dose was decreased to 4 mcq/kgbw/minute, heparin was switched to aspirin 100 mg/kgbw/day = 350 mg/6hour/oral, calnic plus 5 ml/24hour/oral. Nutrition and metabolic disease division: nutritional marasmus management on rehabilitation phase: regular food 3x500 kcal, milk 3x200 kcal, Vitamin B comb 1 tablet/24hour/oral, folic acid 1 mg/24hour/oral, Vitamin C 50 mg/12hour/oral.

**DISCUSSION**

Rheumatoid vasculitis is a blood vessel inflammation that can result in vascular damage. This occurs in venules,

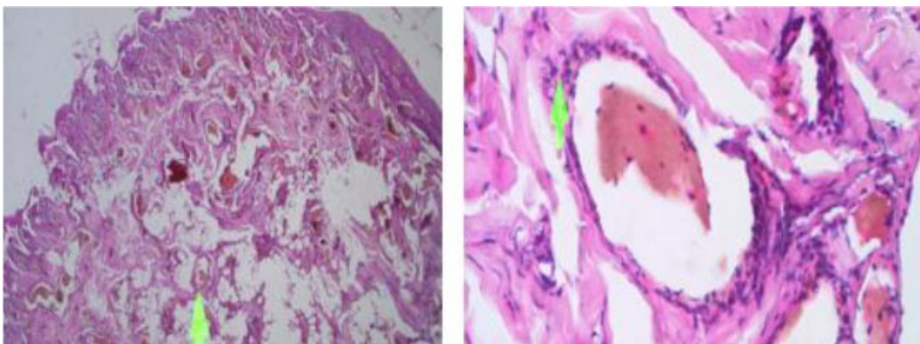


**Figure 3.** Echocardiography

- AV-VA concordance.
- Dilatation of LA-LV
- Intact IAS and IVS
- No PFO ,ASD nor VSD
- Aorta to the left, no evidence of CoA , PA confluence,
- No PDA
- Mild – moderate Mitral regurgitation
- RV systolic is within normal limit

**Impression :**

- decrease systolic LV Ef 35 % with LA/LV dilatation and segmented hypokinetic.
- Mild-moderate mitral regurgitation as in rheumatic heart disease.



**Figure 4.** Tissue biopsy from finger: Vasculitis with angioma can be considered

**Conclusion :** Vasculitis with angioma can be considered.

**Assessment :** right and left heart failure due to acquired heart disease caused by rheumatic heart disease, Peripheral arterial disease, right eye blepharitis, gangrenous digiti I and II left hand, Leukocytosis, reactive thrombocytosis, nutritional marasmus.

capillaries, and arterioles, affecting the skin, peripheral nerves, central nervous system, and internal viscera, resulting in peripheral neuropathy, gangrene and purpura. Vasculitis is mostly found on the skin, 90 % in the form of skin ulcers, foot ulcers, nail fold lesions, and leg ulcers. Skin biopsy provides histologic evidence of skin vasculitis. Vasculitis of blood vessels can cause purpura in tiny blood vessels and ischemia, necrosis, and gangrene in larger blood vessels. Vasculitis can also manifest in the form of urticaria. In the eye, vasculitis can manifest as episcleritis or scleritis and peripheral ulcerative keratitis, with scleritis occurring anteriorly or posteriorly.<sup>2,7,8</sup>

Aside from physical examination, diagnosis of RV should be confirmed by tissue biopsy. In our case, fever, weight loss, edema on the right palpebra, purpura on hands and feet, necrotic tissues on digiti I and II, stiffness and pain on both knees, and laboratory findings of tissue biopsy, all of which support vasculitis. The postulated pathogenic mechanism of RV is complex, involving the activation of the endothelial cells, with upregulated expression of HLA-DQ, interleukin-1 $\alpha$  and expansion of CD28null T cells. Several clinical studies suggest that RV may be caused by circulating immune complexes containing RF and autoantibodies such as antiendothelial cell antibodies, forming deposits in vessel walls and triggering an inflammatory reaction, which may lead to endothelial cell injury.<sup>9,10</sup>

Regarding streptococcus eradication, the suggested measures for streptococcal pharyngitis apply to rheumatic fever and heart disease. Benzathine penicillin G is the first choice recommended. However, the drugs are currently difficult to find and are not available. In case like this, erythromycin is recommended by WHO as primary prophylaxis for rheumatic. Erythromycin given for 10 days is given an initial dose of 40 mg/kgbw/day divided into 4 doses. Maintenance dose 250 mg/12 hours/ orally until 25 years old. Prednisone as anti-inflammatory was given 2mg/kg/day in 3-4 doses for two weeks, then was tapered off to 1 mg/ kg/day for 2-6 weeks. This medication helps to relieve acute inflammatory process, although it doesn't affect the incidence and severity of cardiac



damage caused by rheumatic fever.<sup>11,12</sup>

In our patient, methylprednisolone was given as an anti-inflammatory drug to treat rheumatic heart disease as well as vasculitis, which was characterized by purpura primarily in the upper and lower limbs, necrotic fingers and toes as well as consistent tissue biopsy finding, supporting vasculitis. This patient had severe carditis rheumatic heart disease, therefore aspirin was given over three weeks at a dose of 100mg/kg/day for ten days and then tapered off to 60 mg/kg/day for six to eight weeks. Following the

course of aspirin the RV and blepharitis were improved.

Because there were no contraindications, treatment in this case consisted of administering digitalis in digoxin. Digoxin has both positive inotropic and negative chronotropic effects; increasing myocardial contractility and decreasing heart rate to provide adequate cardiac output. Diuretics are used to reduce heart preload/volume. Furosemide is a widely used diuretics that has been shown to effectively inhibit water and salt reabsorption in the kidney, hence

reducing circulating volume. Captopril is given to reduce heart overload caused by heart failure. Captopril, an ACE inhibitor, blocks renin- angiotensin-aldosterone signaling by inhibiting the conversion of angiotensin I to angiotensin II resulting in vasodilatation and reduced salt retention and aldosterone secretion. Since ACE is also involved in bradykinin degradation, ACE inhibitor will increase bradykinin, a potent vasodilator, and promote the release of prostaglandins and nitric oxide. Increased bradykinin amplifies the blood pressure-lowering action of ACE inhibitors and decreases mortality in individuals with heart failure by about 20%.<sup>11,12</sup>

Regarding streptococcus eradication, the suggested measures for streptococcal pharyngitis apply to rheumatic fever and heart disease. Benzathine penicillin G is the first choice recommended. However, the drugs are currently difficult to find and unavailable in all parts of Indonesia. In case like this, erythromycin is recommended by WHO as primary prophylaxis for rheumatic fever, and is given for 10 days at a dose of 40 mg/kgbw/day divided in 4 doses.<sup>11,12</sup>

Prednisone as anti-inflammatory was given 2mg/kgBW/day in 3-4 doses for 2 weeks, then was tapered off to 1 mg/ kg/day for the next week followed by reduction in dose to none within the next 1 – 2 weeks. Corticosteroids are not given to patients with only arthralgia or polyarthritits but they are given to those who suffered from severe carditis to reduce symptoms of acute inflammation, as seen in our case. Corticosteroid is recommended for rheumatic fever with heart failure. This medication helps to relieve acute inflammatory process, although it doesn't affect the incidence and severity of cardiac damage caused by rheumatic fever.<sup>11,12</sup>

In our patient, anti-inflammatory drug was given in form of methylprednisolone as indicated by rheumatic heart disease as well as vasculitis, characterized by

**Table 1. Jones criteria (revision) for Rheumatic fever diagnosis recommendations (1992)<sup>13</sup>**

Major manifestations	Minor manifestations
Carditis	Clinical :
Polyarthritits migrans	- arthralgia : Joint pain without hyperemia and swelling
	- high fever (39° C)
Chorea Sydenham	Laboratory work:
Erythema marginatum	- increased inflammatory marker such as erythrocyte sedimentation rate (ESR) or C reactive protein (CRP)
Subcutaneous nodules	- prolong PR interval on ECG
Plus	
Evidence of past Group A beta hemolytic streptococcal infections (the last 45 days)	
- Positive throat swab culture or rapid test antigen Group A beta hemolytic streptococcal	
- increased serological titers of Group A beta hemolytic streptococcal antibodies	

**Table 2. Clinical manifestations caused by cardiac valve involvement<sup>13</sup>**

Condition	Manifestations
Mitral regurgitation	- increased left ventricular activities
	- pansystolic murmur on the apex, spreading to axilla and the back
	-Mid-diastolic murmur (carrey cooms murmur) on the apex
Aorta regurgitation	- Increased left ventricular activities
	- Diastolic murmur on left/right ICS II , spreading to apex
	- wide pulse pressure (high systolic while diastolic pressure is very low even reaching 0 mmHg)
Mitral stenosis	- Negative left ventricular activities
	- Diastolic murmur on the apex with loud S1

**Table 3. Rheumatic heart disease anti-inflammatory guide<sup>13</sup>**

	Arthritis	Mild carditis	Moderate carditis	Severe carditis
Prednison	-	-	2-4 weeks	2-6 weeks
Aspirin	1-2 weeks	2-4 weeks	6-8 months	2-4 months

**Table 4. Rheumatic heart disease activity guide<sup>13</sup>**

Activity	Arthritis	Minimal carditis	Moderate carditis	Severe carditis
Bed rest	1-2 weeks	2-4 weeks	4-6 weeks	2-4 months/ so long as heart failure persists
Indoor activities	1-2 weeks	2-3 weeks	4-6 weeks	2-3 months
Outdoor activities	2 weeks	2-4 weeks	1-3 months	2-3 months
Full regular activities	After 6-10 weeks	After 6-10 weeks	After 3-6 months	varies

purpura primarily in the upper and lower limbs, necrotic fingers and toes as well as consistent tissue biopsy finding, supporting vasculitis. Rheumatic fever patients with moderate to severe carditis should be hospitalized. Arthritis or mild carditis patients without heart failure do not need strict bed rest. However, in the presence of severe carditis (with heart failure), the patient must rest completely for at least during corticosteroid treatment. The recommended bed rest is for 6-8 weeks.<sup>11,12</sup>

A 2014 case-control study found a significant reduction in RV risk. Two widely used drugs, hydroxychloroquine (HCQ) and aspirin were found to inhibit the development of Rheumatoid Vasculitis. In systemic rheumatoid vasculitis (RV) or RV that is confined to one organ (for example eye disorder or neuropathic vasculitis), aggressive treatment with immunosuppressive agent such as high dose glucocorticoids alongside rituximab or cyclophosphamide is needed. In one study conducted in 1989, the effects of prednisone paired with azathioprine were studied in 28 patients with RV. Nine patients with severe systemic vasculitis were treated with daily 60 mg prednisone and 2 mg/kgBW azathioprine, all showed improvement in the symptoms. Systemic RV therapy aims to induce remission, defined by the absence of active vascular inflammation and the relief of symptoms.<sup>14</sup> With early diagnosis and proper treatment, most children with vasculitis can achieve remission and live normal lives.

## CONCLUSION

Childhood vasculitis is a condition are multisystem involvement and require integrated care from multiple subspecialties, in this patient were care by cardiology, intensive care unit, vascular surgery, hematology and nutrition. With early diagnosis and treatment of RV is possible to control symptoms of RV and prevent or minimize organ damage.

## DISCLOSURES

### Funding

The author(s) not receive financial support from any organization or party for the

research, authorship, and/or publication of this article.

### Consent for Publication

The patient's parents have agreed to publish this article for academic purposes with the condition of not including the identity (patient's name).

### Conflict of Interest

The author(s) declare that there is no potential conflict of interest from anywhere regarding this article's research, authorship and/or publication.

### Author Contribution

SAL, MMN, DM and HMH were involved in drafting the Article Concept, then designing was done by DM and HMH, in making the Definition of intellectual content was done by SAL and MMN, followed by Literature search involving all authors of SAL, MMN, DM and HMH, then for clinical studies were conducted by SAL and DM, and experimental studies were conducted by MMN and HMH. The data acquisition was performed by DM and HMH, while the data analysis was carried out by DM, HMH and SAL. For statistical analysis it was only done by MMN, then for manuscript preparation it was done by SAL, followed by manuscript editing done by all the authors from SAL, MMN, DM and HMH then the part for reviewing manuscripts was MMN and SAL, and the one who acted as guarantor was SAL.

## ACKNOWLEDGMENTS

We acknowledge the support received from Bali Medical Journal. The authors also thank the reviewers for their valuable comments to revise case report and we would like to thank, in particular, the patience, attention, and support of other authors' contributions as well as some of the participation that contributed to the completion of this article.

## REFERENCES

1. Bartels C.M, Bridges A.J. Decline in rheumatoid vasculitis prevalence among US veterans Arthritis Rheum. 2010 Dec;12(6):414-419.

2. Gardner M, Dolezalova P. Vasculitis in children: incidence and classification. 2002;360(9341):1197.
3. Watkins DA, Johnson CO, Colquhoun SM, Karthikeyan G, Beaton A, Bukhman G, Forouzanfar MH, Longenecker CT, Mayosi BM, Mensah GA, Nascimento BR, Ribeiro ALP, Sable CA, Steer AC, Naghavi M, Mokdad AH, Murray CJL, Vos T, Carapetis JR, Roth GA. Global, Regional, and National Burden of Rheumatic Heart Disease, 1990-2015. N. Engl. J. Med. 2017 Aug 24;377(8):713-722.
4. Narenza CD, Habibie YA. A challenging triple valve surgery for long-standing pulmonary hypertension in rheumatic heart disease: a case report. Bali Medical Journal. 2023 Jan 25;12(1):404-9.
5. Gerber MA. Group A Streptococcus. In: Behrman RE, Kliegman RM, Jenson HB, Stanton BF. In : Nelson textbook of pediatrics; 18<sup>th</sup> ed. Philadelphia: WB Saunders Co. 2007;1140-45.
6. Madiyono B, Rahayuningsih SE, Sukardi R. Demam rheumatik akut dan penyakit jantung rheumatik. Dalam : Penanganan penyakit jantung pada bayi dan anak Jakarta: Departemen Ilmu Kesehatan Anak FKUI RSCM FKUI. 2009:95-14.
7. Anja S and Chrastian M. Childhood vasculitis, Frontiers in pediatric. 2018;6:42.
8. Sutawan IB, Putera AM, Hikmah Z, Endaryanto A. Urticarial vasculitis associated with post-streptococcal disease in children: a case report. Bali Medical Journal. 2023 Feb 1;12(1):501-5.
9. Abdulqader Y, Al-Ani M, Parperis K. Rheumatoid vasculitis: early presentation of rheumatoid arthritis. Case Reports. 2016 Nov 8;2016:bcr2016217557.
10. Scott DG, Bacon PA. Intravenous cyclophosphamide plus methylprednisolone in treatment of systemic rheumatoid vasculitis. Am J Med. 1984 Mar;76(3):377-84. doi: 10.1016/0002-9343(84)90654-5. PMID: 6142648.
11. Rilantomo, LI. Penyakit Kardiovaskular (PKV), Jakarta: fakultas kedokteran Universitas Indonesia. 2013:331-335
12. Park MK. Acute rheumatic fever. In: Pediatric cardiology for practitioners. 6<sup>th</sup> ed. Philadelphia: saunders. 2014:343-464
13. ikatan Dokter Anak Indonesia. Pedoman Pelayanan Medis, Ed.2.Jakarta :Publishing agency Ikatan Dokter Anak Indonesia. 2011:41-42
14. Heurkens AH, Westedt ML, Breedveld FC. Prednisone plus azathioprine treatment in patients with rheumatoid arthritis complicated by vasculitis. Arch Intern Med. 1991;151(11):2249



This work is licensed under a Creative Commons Attribution